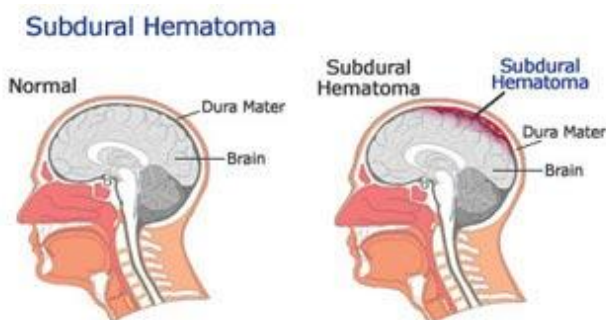


## Craniotomy & Evacuation of Subdural Haematoma

If a subdural haematoma is small and there are no neurological deficits, it can often be monitored with regular CT-scans with the possibility it will resorb itself in time. The presence of any neurological deficits or progressive signs of raised intracranial pressure (increasing headache, nausea, vomiting) will indicate surgery is needed.



© Dementia Information Page: [www.about-dementia.com](http://www.about-dementia.com)

### OPERATION

Two types of surgeries are used to treat subdural haematomas, the choice of which depends on the type and age of the subdural, the radiological appearance and patient co-morbidities.

#### Craniotomy & evacuation of Subdural Haematoma

In general a craniotomy to remove the thick clot is performed for an acute subdural. A general anaesthetic will be given and an incision made overlying the site of the extradural haematoma. A small piece of skull bone is removed (craniotomy) and the covering of the brain opened (durotomy). The blood clot will be found here and removed. Any obvious sites of bleeding are stopped with the diathermy. A drain is may then be placed in the subdural space. The bone is then replaced and secured with titanium plates and staples placed in the skin.

#### Burr-hole drainage of Subdural Haematoma

A burr-hole drainage is usually performed for chronic subdural haematomas. One or usually two burr-holes will be performed over the maximal site of the haematoma. The dura is then opened and the haematoma washed out with copious amounts of irrigation. A drain may then be placed and the skin wounds closed with staples.

Your surgeon will discuss these options with you prior to surgery.

#### **Risks of the procedure:**

The risks of this operation includes the following. A detailed discussion with your surgeon is recommended prior to surgery.

- Infection – superficial wound infection or deeper infections including meningitis, osteomyelitis.
- Bleeding – which may be superficial or deeper with reaccumulation of haematoma requiring a second operation.
- Epilepsy which may require medication.
- Permanent neurological damage in the form of weakness, numbness, paralysis.
- Loss of smell.
- Coma or death.

#### **Long term effects:**

Recovery from a subdural haematoma is dependent on the degree of underlying brain damage incurred at the time of injury and prior to surgical treatment. Some people will return to their normal lives with no change or difficulty whilst others may suffer irreparable brain damage and become fully dependent on external care. Concomitant brain injury may result in seizures requiring treatment with anti-epileptic medications. Occasionally a subdural may reform before the brain re-expands into the skull cavity and a second operation may be indicated.