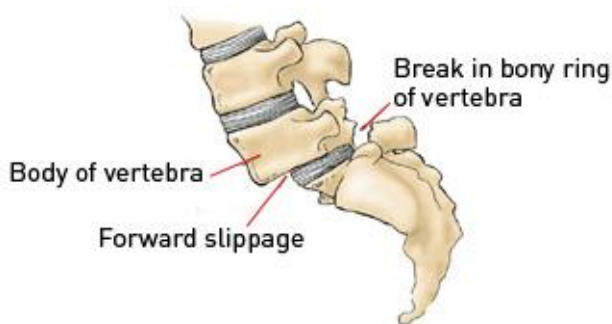




Lumbar Spondylolisthesis

The lumbar spine consists of alternating bony vertebrae and intervertebral discs. It is the major weight-bearing portion of the spine and is involved in the movements of bending forwards and backwards. The spine is maintained in perfect alignment by the facet joints and ligaments connecting each adjacent vertebrae and trunk muscles (back and abdominal) which give support and strength. Failure of any of these elements may result in instability of the spine and lumbar spondylolisthesis, most commonly seen as the vertebra above slips forwards on the vertebra below.



© University of Michigan Health System

CAUSE

Spondylolisthesis means there is a malalignment of the spinal column with slippage of one vertebra on another with resultant compromise of the spinal canal. It may be:

- A congenital disorder of the spine due to failure of the 'pars interarticularis' to form, essentially leading to mobile facet joints.
- A result of trauma causing a fracture or tear in the facet joints or ligaments, or
- Simply a degenerative condition due to wear and tear of the joints and ligaments.

The severity of spondylolisthesis is graded according to the extent of movement of one vertebra on the adjacent vertebra.

SIGNS AND SYMPTOMS

Patients with spondylolisthesis may remain asymptomatic throughout their life and be diagnosed incidentally through x-rays of the lumbar region.

A variety of symptoms may occur in lumbar spondylolisthesis and are depend on the degree of lumbar canal stenosis associated. These include:

- Back pain.
- Sciatica.
- Neurogenic claudication.
- Cauda equina syndrome.

Back Pain

Chronic low back pain radiating to the hips and buttocks may be present. This may be worsened with any back movements.

Sciatica

Stenosis in the lateral (side) regions of the lumbar canal may result in pressure on the exiting nerve roots. The nerve roots supply power and sensation to the legs and severe radicular pain (pain shooting into the leg) may occur in a specific nerve distribution. Numbness and tingling may also occur in the same region.

Neurogenic claudication

This is pain running down both legs that get worse with walking and limits the distance you can walk. It is usually a cramp-like pain but occasionally may be burning in sensation. It is due to central lumbar canal stenosis that causes pressure on the cauda equina as you move.

Cauda equina syndrome

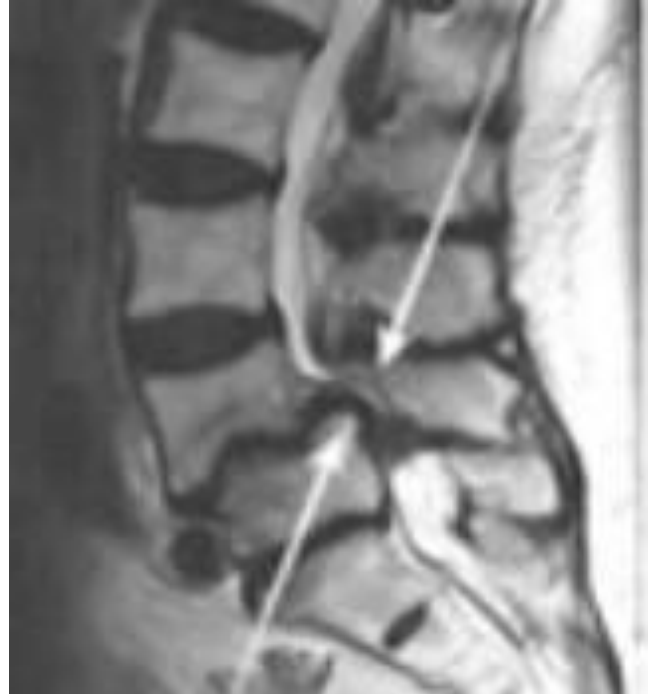Persistent severe pressure on the cauda equina may result in cauda equina syndrome. This includes:

- Numbness around the bottom and anus.
- Impotence or sexual dysfunction.
- Loss of bowel or bladder control.



INVESTIGATIONS

- Plain x-rays – Dynamic x-rays will be taken in flexion and extension may be performed to document any instability. Plain x-rays do not give any information on nerve root or spinal cord compression but may demonstrate a pars defect.
- CT lumbar-spine – this is usually ordered by the GP for low back pain/radicular symptoms. It gives some information on bony alignment and may demonstrate an obvious pars defect. Occasionally it is combined with a myelogram to demonstrate any functional compression/obstruction.
- MRI lumbar-spine – this is the gold standard in looking at lumbar spondylolisthesis and to delineate the degree of nerve root or cauda equina compression. It will also give information as to the cause of the spondylolisthesis.



Sagittal MRI demonstrating lumbar spondylolisthesis at the L4/5 level

The presence of intractable radicular pain and neurological deficit is an indication for operative neurosurgical treatment. Neurosurgical treatment aims to relieve symptoms via decompressing nerves and with or without stabilising the spine (fusion).