

Cervical Disc Prolapse

The human spine consists of alternating bony vertebrae and intervertebral discs extending from the neck to the coccyx. The upper portion of the spine in the region of the neck is called the cervical spine. This portion allows movement of the neck and supports the head during head movements. The intervertebral discs are the 'shock absorbers' of the body and are composed of an outer strong fibrous membrane and an inner 'jelly-like' nucleus giving both strength and elasticity.

A disc prolapse occurs when there is a weakening in the outer membrane leading to a protrusion of the inner nucleus. This protrusion usually heads posterolaterally towards the lateral parts of spinal canal which contains the nerve root. Occasionally the protrusion heads more centrally and can cause compression of the spinal cord.

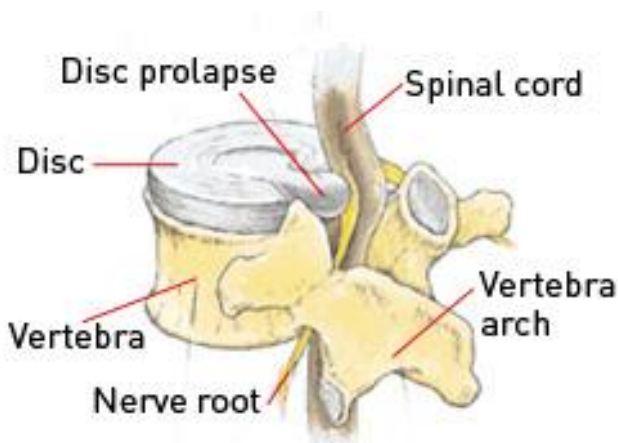


Image © Martin Dunitz 2001, from *Sports Injuries: Their Prevention and Treatment, 3rd Edition*, by Lars Peterson and Per Renstrom, published by Martin Dunitz Ltd, www.dunitz.co.uk

CAUSE

There is no known cause of cervical disc prolapses. Heavy lifting and straining may exacerbate the condition. Traumatic disc prolapses may occur with localised high velocity pressure. The presence of any associated cervical canal stenosis will result in a higher likelihood of neurological symptoms with a cervical disc prolapse.

SIGNS AND SYMPTOMS

A variety of symptoms are present with a cervical disc prolapse may occur due to the acute disc rupture itself, and any pressure that may occur on neurological structures as a result and includes:

- Neck pain.
- Radicular (arm) pain.
- Focal neurological deficits (weakness, numbness, tingling).
- Myelopathy.

Neck Pain

Severe neck pain radiating to the back of the head and down between the shoulder blades may be present with an acute disc prolapse. This is due to the sensory innervation of the disc annulus itself. There will often be associated muscle spasm, aimed at limiting movement of the neck and relieving pain. However, spasm in itself may cause generalised neck pain.

Radicular (arm) pain & Focal Neurological Deficits

A postero-lateral disc prolapse may result in pressure on the exiting nerve roots. The nerve roots supply power and sensation to the arms and severe radicular pain (pain shooting into the arm) may occur in a specific nerve distribution. Numbness and tingling may also occur in the same region. Continued pressure on the nerve roots may result in permanent damage and weakness of the arm.

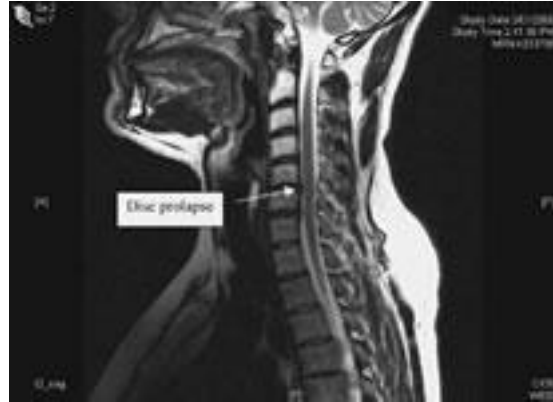Myelopathy

A large or central disc prolapse may result in pressure on the spinal cord. This may result in disruption of the nerve signals to the legs and cause spastic legs, hyper-reflexic legs and difficulty walking (myelopathy). It may also result in radicular symptoms with pain shooting into the arms, torso or legs. There may also be loss of control of the bowel and bladder function.



INVESTIGATIONS

- Plain x-rays – these are usually taken to rule out any fracture or malalignment. Dynamic x-rays taken in flexion and extension may be performed to document any instability. Plain x-rays do not give any information on nerve root or spinal cord compression.
- CT C-spine – this is usually ordered by the GP for neck pain/radicular symptoms. It gives some information on bony alignment but often fails to demonstrate a disc prolapse. Occasionally it is combined with a myelogram to demonstrate any functional compression/obstruction.
- MRI C-spine – this is the gold standard in looking for cervical disc prolapses and to delineate the degree of nerve root or spinal cord compression.



MRI of Cervical Disc Prolapse

The presence of intractable radicular pain and neurological deficit is an indication for operative neurosurgical treatment. Neurosurgical treatment aims to relieve symptoms via decompressing nerves and with or without stabilising the spine (fusion).